International Journal of Pharmacy and Medicine Sciences
Vol. 2, Issue 10, October 2026 *CAS CODEN (USA): IJPMIY*
ISSN: 3108-009X **DOI:** https://doi.org/10.5281/zenodo.23813283

Open Access RESEARCH

Phytochemical and Synergistically Combined Anti-Inflammatory Activity of *Annona Squamosa* (Seeds) And *Ficus Racemosa* (Leaves)

[1]Shalu Tripathi, [2]Prof. (Dr.) Shobhit Prakash Srivastava, [3]Mohit Kumar Soni, [4]Kavita Pandey

[1]Research scholar, Dr. M.C. Saxena college of Pharmacy, Lucknow, Uttar Pradesh
[2*]Professor, Dr. M.C. Saxena college of Pharmacy, Lucknow, Uttar Pradesh
[3,4]Dr. M.C. Saxena college of Pharmacy, Lucknow, Uttar Pradesh

***Submission**: October 21, 2026; **Revised**: October 27, 2026; **Published**: October 31, 2026*

Corresponding author:
[2]Prof. (Dr.) Shobhit Prakash Srivastava
[2*]Professor, Dr. M.C. Saxena college of Pharmacy, Lucknow, Uttar Pradesh
Email id: tripathikhushi03@gmail.com

ABSTRACT

The present study investigates the phytochemical composition, safety profile, and anti-inflammatory activity of plant extracts derived from *Annona squamosa* seeds and *Ficus racemosa* leaves. Phytochemical screening revealed that the biological activity of these plants is attributed to the presence of diverse secondary metabolites, which vary depending on the solvent used for extraction. Methanolic extract of *Ficus racemosa* was found to contain steroids, flavonoids, phenolic compounds, tannins, carbohydrates, quinones, saponins, and glycosides, while lacking terpenoids, proteins, and alkaloids. In contrast, the ethanolic extract of *Annona squamosa* contained steroids, flavonoids, carbohydrates, saponins, glycosides, and alkaloids, but was devoid of terpenoids, phenolics, quinones, tannins, and proteins. Acute toxicity studies demonstrated that the extracts are safe, with no mortality or behavioral abnormalities observed in animals up to an oral dose of 2000 mg/kg. No significant changes in body weight, morphology, or physiological behavior were noted, indicating that the LD_{50} of the polyherbal formulation exceeds 2 g/kg. Based on these findings, doses of 100, 200, and 400 mg/kg were selected for pharmacological evaluation.
The anti-inflammatory activity was assessed using an egg white-induced paw edema model in rats. The results showed that the combination of extracts exhibited significant ($p<0.001$) inhibition of edema, particularly at ratios of 1:2 and 2:1. The 1:2 ratio demonstrated 38.32% inhibition, comparable to the standard drug indomethacin (38.52%), indicating strong anti-inflammatory potential. The effect is likely mediated through inhibition of inflammatory mediators such as histamine, serotonin, kinins, and prostaglandins, particularly during the second phase of inflammation. Histopathological analysis confirmed reduced edema and leukocyte infiltration in treated groups compared to control. Overall, the study concludes that the combined extracts exhibit significant and synergistic anti-inflammatory activity with a high safety margin, suggesting their potential as promising candidates for the development of novel anti-inflammatory agents.

Keywords: *Annona squamosa*, *Ficus racemosa*, anti-inflammatory, histopathological, prostaglandins, histamine.

INTRODUCTION

Medicinal plants include hepatoprotective medicines. Liver diseases have been treated using mono- and poly-herbal treatments. Therapeutic usage of about 700 mono and poly-herbal decoctions, tinctures, tablets, and capsules from 100 plants is estimated. Hepatoprotectants help the liver [1]. However, hepatotoxic drugs harm the liver. Clinical investigations have shown herbal liver treatments work. Paper highlights hepatic and gall bladder herb research [2].

According to WHO, traditional, complementary, and integrative medicine (TCIM) is used by billions of people worldwide. The recently adopted WHO Global Traditional Medicine Strategy 2025–2034 focuses on strengthening research, safety, regulation, and integration of traditional medicine into healthcare systems

while ensuring scientific validation and patient safety [3]. Recent scientific studies have explored Ayurvedic phytochemicals for anti-inflammatory, antioxidant, anticancer, and immunomodulatory activities. Modern research is increasingly focusing on standardization, pharmacological validation, and integration of Ayurveda into evidence-based medicine [4][5].

Natural plants various metabolites are widely utilized in a different kind of infections and inflammation as traditional medication [6]. Extracts of medicinal plants are reported as excellent folk medicine for anti-inflammatory agents worldwide. They are rich sources of phytochemicals applied as herbal medicines and a reasonable basis for producing new anti-inflammatory drugs [7]. Isolated compounds from extracts of medicinal plants are also reported for their effective anti-inflammatory uses [8][9].

Custard apple, also referred to as, is a member A. squamosa of the Annonaceae family of garden plants. A. squamosa leaves include active substances like flavonoids, glycosides, phenolics, tannins, phytosterols, alkaloids, and saponins. Only a few of the therapeutic advantages these chemicals display include antioxidants, anticancer, antibacterial, antiviral, anti-melanogenic, and anti-inflammatory properties. In A. squamosa extracts, leaves, and seeds, four A. squamosa alkaloids were found, including anonaine, asimilobine, nur nuciferine, liriodenine, corypalmine, and reticuline [10].

Ficus racemosa Linn. (Moraceae) is a popular medicinal plant in India, which has long been used in Ayurveda, the ancient system of Indian medicine, for various diseases/disorders including diabetes, liver disorders, diarrhea, inflammatory conditions, hemorrhoids, respiratory, and urinary diseases. The leaves contain triterpenoids tannins, kaempferol, rutin, arabinose, bergapten, psoralenes, flavonoids, ficusin, coumarin, phenolic glycosides and saponins [11].

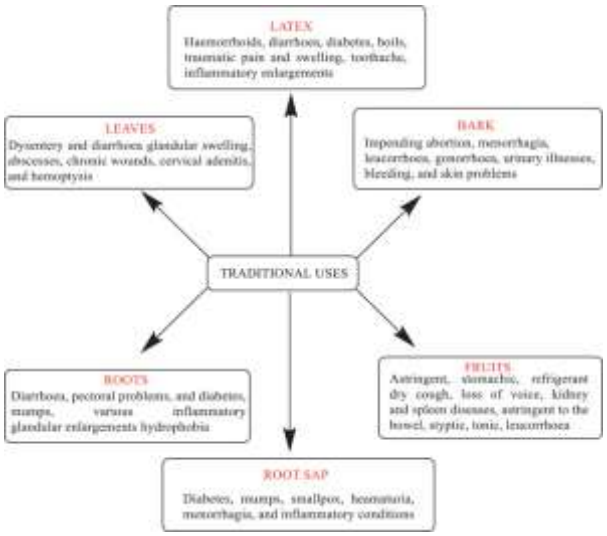

Fig 1. Uses of Ficus racemosa [12]

MATERIALS

Annona squamosa seeds and Ficus racemosa leaves were procured January 2026, from local vendors in Lucknow, Uttar Pradesh, India. A plant geneticist from the [ICAR-(National Bureau of Plant Genetic Resources)] (NBPGR) in New Delhi, Dr. K.C. Bhatt, verified the authenticity of the seeds and leaves (Voucher No. (AC - 19/2026).

METHODS

I. **Extraction**

1) **Extraction of *Annona squamosa*:** After being let to dry in the shade at room temperature, the seeds of Annona squamosa were pulverised using a mechanical grinder and then passed through 40 meshes of sieves. In 250 ml of 80% ethanol, 20 grammes of powdered seeds were extracted using a Soxhlet apparatus until the solvent was completely used up. The concentrate was subjected to low pressure. Studies on phytochemicals and anti-inflammatory properties were conducted using this semi-solid mass, which did not include ethanol [13].



Fig 2. Collection and powdered drug of Annona squamosa seeds

1) **Extraction of *Ficus racemosa*:** There will be days of sun-drying the plant leaves. For better grinding, the plant materials will be low-temperature oven-dried for 24 hours. Using a high-capacity grinder, the dried leaves will be ground into a coarse powder. Pour 3.5 litres of methanol over 650 grammes of powdered material in a clean, 5-liter round-bottomed flask. For 15 days, while shaking and stirring occasionally, seal the jar with a cotton plug and aluminium foil. A Heidolph rotary evaporator will be used to condense the mixture at 390C after filtering it using cotton and Whatman No.1 filter paper. The concentrated extract leaves a solid byproduct when air-dried. You may get the weight of the crude methanol extract from the powdered plant [14].



Fig 3. Collection and powdered drug of *Ficus racemosa* leaves

II. **Preliminary phytochemical screening:** According to our previous research, the newly obtained raw extracts were qualitatively examined for secondary metabolites like glycosides, alkaloid compounds, sugary carbohydrates, proteins, saponins, steroids, tannins, coumarins, phenols, and flavonoids.

III. **Physico-chemical Evaluation:** Morphological and microscopic analysis of powdered Ficus racemosa leaves and Annona squamosa seeds was performed which included tests of Powder microscopy, Moisture content, Ash Value, Total Ash, Acid-insoluble ash values, Water-soluble ash values, Extractive Value, Extractive value soluble in alcohol, Estimation of extractive value soluble in water.

IV. **Experimental Study**

A Wistar albino rat weighing 150-220 grammes will be utilised. Temperature of 23 degrees Celsius and a light/dark cycle of 12 hours each will be maintained for the animal. Their food and water supply is endless. In the seven days leading up to the study, the animals will be allowed to acclimatise. Animals will only be obtained from accredited institutions or CDRIs. All research using animals must adhere to the standards set out by the CPCSEA and the IAEC.

V. **Acute Toxicity Studies**

" The "Acute Oral Toxicology Study (Acute Toxic Class Method)" was conducted in wistar rats according to the guidelines laid down by OECD 423 on December 17, 2001.

For every stage, three adult Wistar rats were used. Once the rats had fasted for sixteen hours, they were given a single oral dose of the herb mixture (1:1) at 2000 mg/kg. The dose was 2000 milligrammes per kilogram of body weight. The AF1, AF2, and NC groups were each comprised of three animals. One millilitre of a 0.9% saline solution was given orally to the normal control group (NC) after they fasted overnight, whereas the treatment groups (AF1, AF2) were given aqueous extract once. To dissolve the aqueous extract, 2% tween 20 was used.

1) **Observations:** Following the administration of the differential, the animals were monitored continuously for four hours, and then on an hourly basis for 24 hours, 48 hours, and three days. employs a singular extraction to examine mortality, behavioural alterations, and other physiological occurrences [15]. All observations were recorded using species-specific documentation. Alterations in demeanour, eye colour, hair texture, mucous membranes, and behaviour were observed. Symptoms including tremors, convulsions, salivation, diarrhoea, lethargy, somnolence, and mortality were documented. A modification in wellbeing indicators was seen in comparison to the control group.
2) **Pharmacological Evaluation of Anti-inflammatory Activity: egg Albumin-induced inflammation model:** Okoli and Akah [16] showed that egg albumin-induced inflammation was synergistically influenced by both plant extracts in varying ratios (1:1, 1:2/2:1). All medications were taken orally. Each of the five groups of six rats participated in the experiment after a night of fasting and a day of free water. Group I (control) received (0.5 ml normal saline, p.o.), Group II (positive control) received 10 mg/kg indomethacin), test Group 3 received mixture of extract of A. squamosa (100 mg/kg body weight) and Ficus racemosa (200mg/kg) by subcutaneously in ratio of 1:2; test Group 4 received mixture of extract of A. squamosa and Ficus racemosa in ratio of 2:1 by subcutaneously in ratio of 1:2; test Group 5 received mixture of extract of A. squamosa and Ficus racemosa by subcutaneously in ratio of 2:2. 5% w/v of acacia mucilage was used as a vehicle at a dose of 5 mL/kg. Thirty minutes after administration, inflammation was induced by sub-plantar injection of 0.1 ml of fresh undiluted egg albumin. The white portion of the egg was delicately extracted from the yolk using a 1-milliliter syringe. A total of four hours after inflammation, the treated paw still had not dissipated any distilled water. Afterwards, the fractions were analysed using the identical procedure with the maximum

dosage of ME. At intervals of half an hour to four hours, the inhibitory effect on paw oedema in each case was compared to that of the negative control.

$$\text{Inhibition of edema}\,(\%) = 100\left(1 - \left(\frac{a-x}{b-y}\right)\right),$$

3) x prior to, b following, and y preceding the injection of egg albumin; a represents the average amount of paw oedema in the treated animals.

VI. **Histopathology of Paws:** Rats were killed for histological purposes while under anaesthesia. Paw tissue from all groups was fixed in 10% buffered formalin and stained with hematoxylin and eosin to assess rat paw inflammation (17).

VII. **Statistical Analysis:** All values are reported as mean ± SEM. The percentage variance was assessed for each group. Student's t-test assessed significance.

RESULTS AND DISCUSSION

Primary phytochemical screening of *Ficus racemosa and Annona squamosa* seed extract

Plant extracts preserved in ethanol and methanol either contained or did not include secondary metabolites such as alkaloids, tannins, saponins, phenols, carbs, flavonoids, proteins, amino acids, glycosides, and many more. In contrast to terpenoids, proteins, and alkaloids, methanol extracts of Ficus Racemosa include glycosides, quines, carbs, phenolic chemicals, tannins, and steroids. There are no terpenoids, phenolic compounds, quinones, tannins, or proteins in the ethanolic extract of Annona squamosa; nevertheless, it does include alkaloids, glycosides, carbs, saponins, and flavonoids.

Table 1: Primary phytochemical screening of *Ficus racemosa* and *Annona squamosa* extract with different constituents

S.NO	CONSTITUENTS	*Annona squamosa Ethanol extract*	*Ficus racemosa* methanol extract
1	Steroids	++	++
2	Terpenoids	-	-
3	Phenolic compounds	-	++
4	Flavonoids	++	++
5	Quinones	-	++
6	Tannins	--	++
7	Carbohydrates	++	++
8	Saponins	+++	+++
9	Glycosides	++	++
10	Proteins	-	-
11	Alkaloids	++	-
Key: +++ =High, ++ =Moderate, + =Normal concentration, - = Absent			



A. B.

Fig 4. Phytochemical screening of (A) *Ficus Racemosa* and (B) Annona Squamosa seed extracts

Physico-chemical Evaluation: The drug powder was used to ascertain the drying loss, total ash, water-soluble, and acid-insoluble ash values, and extractive values for Annona squamosa and Ficus racemosa, including water-soluble, alcohol-soluble, and non-volatile ether-soluble values.

Table 2. Physico-chemical Evaluation of powdered drugs of *Annona squamosa*, *and Ficus racemosa*

S.NO	Parameters	Values % W/W *Annona squamosa Ethanol extract*	Values % W/W *Ficus racemosa* methanol

			extract
1	Moisture Content	6.80 ± 0.30	12.3 ± 0.2
2	Total ash	1.89 ± 0.02	12.7 ± 0.5
3	Acid insoluble ash	0.52 ± 0.2	0.7 ± 0.1
4	Water soluble ash	2.03± 0.2	3.1 ± 0.2
7	Water soluble extractive value	18.62± 0.5	16.3 ±0.3
8	Ethanol soluble extractive value	08.75± 0.2	4.3 ± 0.2
9	Non-volatile ether soluble extractive value	3.28±0.3	1.7 ± 0.2

Acute toxicity study

In the acute toxicity study, mice exposed to doses of the plant extract up to 2000 mg/kg showed no signs of death or behavioural changes. Future studies will employ doses of 100, 200, and 400 mg/kg of rat body weight, as determined by the preliminary toxicity test.

During the test period, animals did not die after receiving a single oral dose of a 1:1, 2:1, or 1:2 mixture of the two extracts.

While being observed, the appearance of the beings remained unchanged. Its skin, hair, eyes, and nose were all unharmed. Without tremors, convulsions, salivation, diarrhoea, lethargy, self-mutilation, or reverse walking, the animals who were treated showed no signs of these problems. There was no statistically significant difference in weight between the pre- and post-study periods (Figure 5). Seeing a decline in body weight after being exposed to potentially hazardous substances is a simple and sensitive way to gauge toxicity. The results showed that after two weeks of healthy behaviour free of poisoning, all six mice survived the experiment. Animals up to 2 g/kg can be administered either plant extract or the polyherbal formulation, since the acute oral LD50 in rats is more than 2 g/kg.

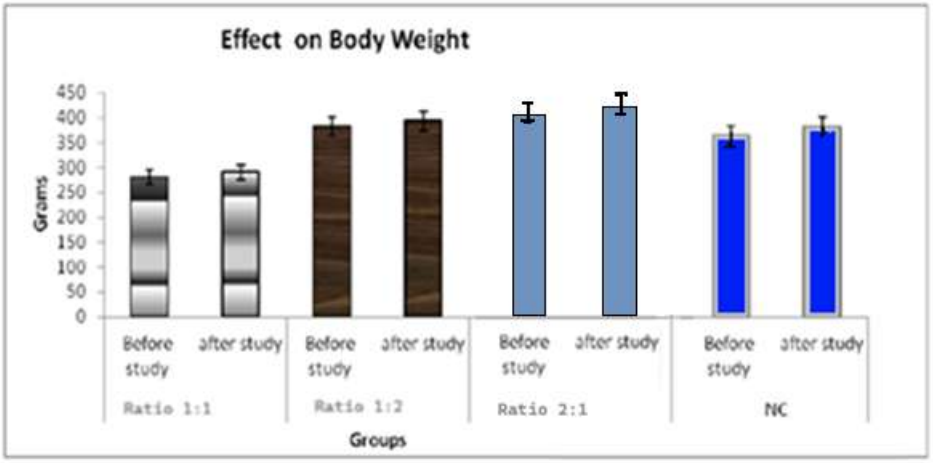

Fig 5. Effect of mixture 1:1, 1:2 and 2:1 on body weight changes in the acute toxicity study. Each bar represents mean±SEM (n=5)

Anti-inflammatory activity

Annona squamosa seed and Ficus racemosa leaf extracts, in a 1:2 ratio (100 mg/kg+ 200mg/kg), considerably decreased oedema. There is a possibility of oedema due to the allergens and protein in egg whites. Identifying the particular protein fraction that causes oedema requires more research because egg white proteins might have unique pro-and/or anti-inflammatory actions. Egg white was discovered to induce swelling of the rat paws in the investigation. Subcutaneous egg white injection caused oedema, which was most noticeable in the second hour after administration. Egg white-induced oedema can be caused by the release of histamine and serotonin.

Histamine and serotonin release initiates the initial stage of rat paw oedema. Molecules that resemble kinnin maintain oedema throughout the stages. Compounds that are similar to prostaglandins improve phase two. Hydrocortisone, phenylbutazone, and indomethacin are effective against the second stage of oedema (18). The

cyclooxygenase enzyme is not specifically inhibited by indomethacin (19). In the second phase, carrageenan inflammation is inhibited by the studied A. squamosa F. racemosa plant extract (1:1, 1:2, 2:1). Significant ($p < 0.001$) results are shown in Table 5.3, which are comparable to those of traditional indomethacin. These findings provide credence to the study's stated purpose of reducing inflammation. This study discovered that extracts from the seeds and leaves of A. squamosa and F. racemosa, when used in different proportions, had an anti-inflammatory effect that is synergistic. Group IV, which contained plant extracts prepared at a 1:2 ratio, had the best synergistic anti-inflammatory efficacy when compared to groups II, III, and V, out of the three different ratios tested. Figure 38.32% shows paw volume inhibition in group IV, which is about the same as positive control group II's 38.52%, whereas figures 37-89% and 35.62%, respectively, are shown by groups III and V.

Table 3. Effect of Annona squamosa and Ficus racemosa Linn. extracts mixture in different ratio in egg white induced rat paw oedema

group		% Increase in paw volume Mean ± S.E (n = 6) Post insult time of assay (min)						% Inhibition of Paw volume
		0 min	30 min	60 min	120 min	180min	240 min	
Control (0.5 ml normal saline)	1 ml/kg, p.o.	68.5 ± 4.4	71.2±5.2	75.1 ± 7.3	89.8 ± 5.5	105.6 ± 7.8	113. 06 ± 5.7	--
positive control (indomethacin)	10 mg/kg	65.1 ± 2.4	67.3±2.9	68.4 ± 4.3	76.5 ± 4.5	73.3 ± 3.1*	73.4 ± 3.5*	38.52
Test (AS+FR) 1:1 ratio	100 mg/kg+ 100 mg/kg	63.5±2.4	65.6±3.5	69.2±5.31	72.3±5.3	74.3±5.6*	75.2±3.5*	37.89
Test (AS+FR) 1:2 ratio	100 mg/kg+ 200 mg/kg	65.5±1.4	67.2±3.5	68.6±3.1	70.1±4.3	72.3±2.5*	73.2±1.2*	38.32
Test (AS+FR) 2:1 ratio	200 mg/kg+ 100 mg/kg	64.2±2.3	66.1±4.5	67.4±5.1	69.2±3.3	70.3±1.5*	71.7±8.2*	35.62

All results expressed as Mean ± SEM from six observations *p < 0.001 Vs Control

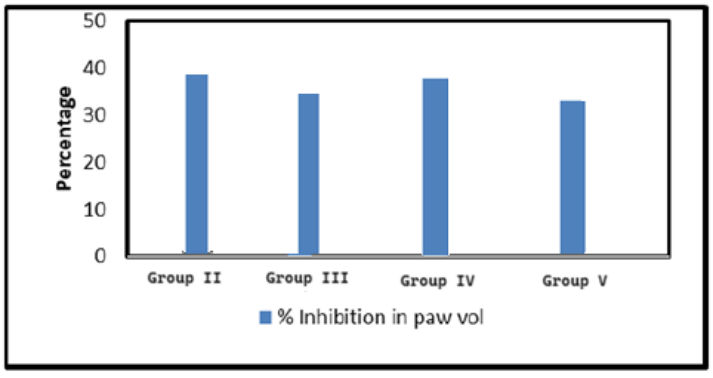

Fig 6. Representation of Percentage of protection of *Annona squamosa* and *Ficus racemosa Linn*. extracts mixture in different ratio

Histopathology of Paw

Subcutaneous injection of egg whites caused a significant increase in paw oedema in rats, in contrast to the lack of swelling in the control group. Histological alterations during inflammation were determined by staining

rat paw tissue with hematoxylin and eosin. This was done for all groups. Compared to the control group, rats inflamed paw tissue showed oedema and leukocyte infiltration after egg white induction (figure 6.).

Injection of egg whites into paw tissue resulted in a high concentration of white blood cells and was associated with the formation of oedema, according to earlier research [20][21][22]. Egg white was discovered to induce swelling of the rat paws in the investigation. Subcutaneous egg white injection caused oedema, which was most noticeable in the second hour after administration. Figure 7. shows that leukocytes were present in the inflamed paw tissues. Egg white-induced oedema can be caused by the release of histamine and serotonin. [23] Previous studies have shown that histamine-induced rat paw oedema reaches its peak one hour after release [24] and that serotonin-induced oedema rises with time (up to three hours) [25]. The acute inflammatory reaction was characterised by histamine and serotonin-induced vascular permeability, oedema, and leukocyte migration [1] and [2].

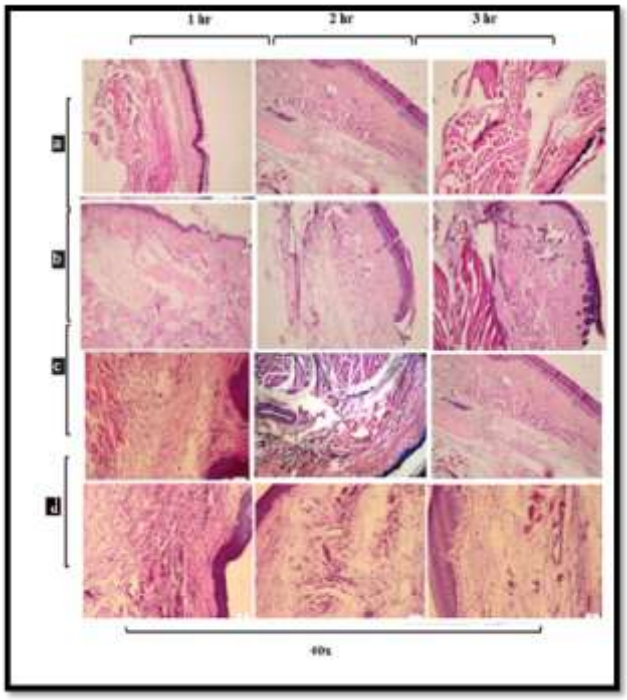

Fig 7. Histological data of paw tissue of (a) group I as normal control, (b) group III as Test (Annona Squamosa + Ficus Racemosa extract) in 1:1 ratio, (c) group IV as 1:2 ratio, and (d) group V as 2:1 ratio, all treated rats after hematoxylin and eosin staining.

DISCUSSION

Plant extracts preserved in ethanol and methanol either contained or did not include secondary metabolites such as alkaloids, tannins, saponins, phenols, carbs, flavonoids, proteins, amino acids, glycosides, and many more. In contrast to terpenoids, proteins, and alkaloids, methanol extracts of Ficus Racemosa include glycosides, quines, carbs, phenolic chemicals, tannins, and steroids. There are no terpenoids, phenolic compounds, quinones, tannins, or proteins in the ethanolic extract of Annona squamosa; nevertheless, it does include alkaloids, glycosides, carbs, saponins, and flavonoids.

In the acute toxicity study, mice exposed to doses of the plant extract up to 2000 mg/kg showed no signs of death or behavioural changes. Future studies will employ doses of 100, 200, and 400mg/kg of rat body weight, as determined by the preliminary toxicity test.

During the test period, animals did not die after receiving a single oral dose of a 1:1, 2:1, or 1:2 mixture of the two extracts.

While being observed, the appearance of the beings remained unchanged. Its skin, hair, eyes, and nose were all unharmed. Without tremors, convulsions, salivation, diarrhoea, lethargy, self-mutilation, or reverse walking, the animals who were treated showed no signs of these problems. There was no statistically significant difference in weight between the pre- and post-study periods (Figure 5.2). Seeing a decline in body weight after being exposed to potentially hazardous substances is a simple and sensitive way to gauge toxicity. The results showed that after two weeks of healthy behaviour free of poisoning, all six mice survived the experiment. Animals up to 2g/kg can be administered either plant extract or the polyherbal formulation, since the acute oral LD50 in rats is more than 2g/kg.

In a 1:2 ratio (100mg/kg+ 200mg/kg), the extracts of Annona squamosa seed and Ficus racemosa leaves shown significant anti-inflammatory activity and reduced oedema. There is a possibility of oedema due to the

allergens and protein in egg whites. Identifying the particular protein fraction that causes oedema requires more research because egg white proteins might have unique pro-and/or anti-inflammatory actions. Egg white was discovered to induce swelling of the rat paws in the investigation. Subcutaneous egg white injection caused oedema, which was most noticeable in the second hour after administration. Egg white-induced oedema can be caused by the release of histamine and serotonin.

Histamine and serotonin release initiates the initial stage of rat paw oedema. Molecules that resemble kinnin maintain oedema throughout the stages. Compounds that are similar to prostaglandins improve phase two. Hydrocortisone, phenylbutazone, and indomethacin are effective against the second stage of oedema (117). The cyclooxygenase enzyme is not specifically inhibited by indomethacin. In the second phase, carrageenan inflammation is inhibited by the studied A. squamosa F. racemosa plant extract (1:1, 1:2, 2:1). Significant ($p < 0.001$) results are shown in Table 5.3, which are comparable to those of traditional indomethacin. These findings provide credence to the study's stated purpose of reducing inflammation. This study discovered that extracts from the seeds and leaves of A. squamosa and F. racemosa, when used in different proportions, had an anti-inflammatory effect that is synergistic. Group IV, which contained plant extracts prepared at a 1:2 ratio, had the best synergistic anti-inflammatory efficacy when compared to groups II, III, and V, out of the three different ratios tested. Figure 38.32% shows paw volume inhibition in group IV, which is about the same as positive control group II's 38.52%, whereas figures 37-89% and 35.62%, respectively, are shown by groups III and V.

Paw histopathology demonstrated that subcutaneous egg white injection significantly produced rat paw oedema, while the control group had no oedema. Rat paw tissue from all groups was stained with hematoxylin and eosin to determine histological changes during inflammation. Egg white induction caused oedema and leukocyte infiltration in inflamed rat paw tissue compared to the control group.

The previous investigation found that egg white injection created a considerable number of leukocytes in paw tissue [20][21] and correlated with oedema development [22]. The study found that egg white caused rat paw oedema. After subcutaneous egg white injection, oedema developed in the 1st h and peaked in the 2nd. Inflamed paw tissues included leukocytes (Fig 6.). Released histamine and serotonin may cause egg white-induced oedema [23]. Previous research indicates that rat paw oedema peaks 1 hour after histamine release [24] and serotonin release causes a time-dependent rise (till 3 hours) [25]. Histamine and serotonin enhanced vascular permeability, oedema, and leukocyte migration during the acute inflammatory response [26][27].

CONCLUSION

According to the study, an alcoholic extract of a 2:1 blend of Ficus racemosa leaves and Annona Squamosa seeds has significant ($p < 0.001$) anti-inflammatory effect and is comparable to the common anti-inflammatory medication Indomethacin. As a result, it has been demonstrated that combining the two plant extracts in a certain ratio produced higher synergistic anti-inflammatory efficacy when compared to both the standard and control groups. Improved anti-inflammatory activity was also observed in the histological data acquired following inflammation induction and treatment, suggesting their synergistic effect. Therefore, an alcoholic extract of a 2:1 mixture of Ficus racemosa leaves and Annona Squamosa seeds shows promise in the development of new anti-inflammatory medications, and additional research on the isolation and fractionation of active components to identify the precise constituents that are responsible for these activities can be considered.

Author contribution

This manuscript was prepared through the combined contributions of all author(s), including contributions to the study design, data, content development, results, interpretation, and related scholarly work.

Conflict of Interest

The authors declare that there are no conflicts of interest

Acknowledgement

The author(s) would like to thank the Director, HOD and department faculties, Dr. M.C. Saxena college of Pharmacy, Lucknow, for providing necessary encouragement and facilities for this work.

CONFLICT OF INTEREST

Authors declare for none conflict of interest.

REFERENCES

[1]. https://www.who.int/teams/integrated-health-services/traditional-complementary-and-integrative-medicine/global-strategies?utm_source=chatgpt.com.

[2]. Roy, S.D., Das, S., Shil, D., Dutta, K.N. Herbal hepatoprotective agents: a review. World journal of pharmaceutical science. 2012;1(2):87-99.

[3]. Oliveira-Costa José Fernando, Meira Cássio Santana, Neves Maria Vitória Gomes das, Dos Reis Bruna Padilha Zurita Claro, Soares Milena Botelho Pereira. Anti-Inflammatory Activities of Betulinic Acid: A Review. Frontiers in Pharmacology. 2022;13.
[4]. Wong YMA, Ahn S, Bana A, Dua PK, Eggers R, Kuruvilla S, Li Y, Liu Q, Shen Y, Kim S. Policy implications of WHO's Global traditional medicine strategy 2025-2034. Bull World Health Organ. 2025;103(11):715-721.
[5]. Patwardhan B, Mutalik G, Tillu G. Integrative Approaches for Health: Biomedical Research, Ayurveda and Yoga. Academic Press; 2023.
[6]. Alam, Faruk, Ruhul Amin, and Biplab Kumar Dey. "A Comprehensive Review on Natural Products and Anti-Inflammatory Activity". Journal of Pharmaceutical Research International. 2021;33(7):57-77.
[7]. Kiani K, Rudzitis-Auth J, Scheuer C, Movahedin M, Lamardi SN, Ardakani HM, Becker V, Moini A, Aflatoonian R, Ostad SN, Menger MD. Calligonum comosum (Escanbil) extract exerts anti-angiogenic, anti-proliferative and anti-inflammatory effects on endometriotic lesions. Journal of ethnopharmacology. 2019;239:111918
[8]. Yang P, Zhu W, Xu J, Liu W, Dong Z, Kikuchi T, Yamada T, Xie N, Feng F, Zhang J. Sesquiterpenoids and triterpenoids from Secamone lanceolata blume with inhibitory effects on nitric oxide production. Fitoterapia. 2019;133:5-11.
[9]. Gonfa, Yilma & Beshah Tessema, Fekade & Joshi, Archana & Rai, Nishant & Getachew, Mesfin & Singab, Abdel Nasser & Chaubey, Kundan & Bachheti, Rakesh. Anti-inflammatory activity of phytochemicals from medicinal plants and their nanoparticles: A review. Current Research in Biotechnology. 2023;6:100152.
[10]. Ahirwar S, Jain S, Nisha P. Annona squamosa L.: A brief review on biological activities and their phytochemicals. Asian J Pharm Pharmacol. 2023;9(1):13-9
[11]. Ahmed, F., & Urooj, A. Traditional uses, medicinal properties, and phytopharmacology of Ficus racemosa: A review. Pharmaceutical Biology. 2010;48(6):672–681.
[12]. Pahari, Nilanjan, Subhabrota Majumdar, Dipanjan Karati and Rana Mazumder. "Exploring the Pharmacognostic properties and pharmacological activities of phytocompounds present in Ficus racemosa linn.: A concise review." Pharmacological Research - Modern Chinese Medicine. 2022;4:100137.
[13]. Umamaheswari, Appavoo & Arunkumar, A & Vedhahari, B & Suryaprabha, D & Punitha, S. Phytochemical Evaluation and Anti-inflammatory Activity of Seed Extract of Annona Squamosa. International Journal of Chemical Sciences. 2018;6: 1594-1599.
[14]. Devi, Nipa Rani. "In Vitro Pharmacological Investigation of Cytotoxic, Antimicrobial and Antioxidant Activity of Aqueous Fraction of Ficus Racemosa Leaves Extract." PhD diss., East West University, 2014.
[15]. Thyagarajan, S.P., Jayaram, S., Gopalakrishnan, V., Hari, R., Jeyakumar, P., Sripathi, M.S., Herbal medicines for liver diseases in India. Journal of Gastroenterology and Hepatology. 2002;17:S370–S376
[16]. Okoli CO, Akah PA, Nwafor SV. Anti-inflammatory activity of hexane leaf extract of Aspilia Africana C.D.Adams. J Ethnopharmacol 2007;109:219–25
[17]. Barung EN, Dumanauw JM, Duri MF, Kalonio DE. Egg white-induced inflammation models: A study of edema profile and histological change of rat's paw. J Adv Pharm Technol Res. 2021;12(2):109-112.
[18]. R. Vineger, W. Schreiber, and R. Hugo, J. Pharmacol. Exp. Ther., 1969;96:166.
[19]. C. Yuh-Fung, T. Huci-Yann, and W. Tian-Shung, Anti-inflammatory and Analgesic Activities from Roots of Angelica Pubescens, Planta Med., 1995;61:2-8.
[20]. Silva FR, Dore CM, Marques CT, Nascimento MS, Benevides NM, Rocha HA, et al. Anticoagulant activity, paw edema and pleurisy induced carrageenan: Action of major types of commercial carrageenans. Carbohydr Polym 2010;79:26-33.
[21]. Park SM, Lee TH, Zhao R, Kim YS, Jung JY, Park CA, et al. Amelioration of inflammatory responses by Socheongryong-Tang, a traditional herbal medicine, in RAW 264.7 cells and rats. Int. J. Mol. Med. 2018;41:2771-83.
[22]. Coura CO, Souza RB, Rodrigues JA, Vanderlei Ede S, de Araújo IW, Ribeiro NA, et al. Mechanisms involved in the anti-inflammatory action of a polysulfated fraction from Gracilaria cornea in rats. PLoS One 2015;10:e0119319
[23]. Akindele AJ, Oladimeji-Salami JA, Usuwah BA. Antinociceptive and anti-inflammatory activities of Telfairia occidentalis hydroethanolic leaf extract (Cucurbitaceae). J Med Food. 2015;18:1157-63.
[24]. Tamaddonfard E, Farshid AA, Hosseini L. Crocin alleviates the local paw edema induced by histamine in rats. Avicenna J Phytomed 2012;2:97-104.
[25]. Sowemimo A, Onakoya M, Fageyinbo MS, Fadoju T. Studies on the anti-inflammatory and anti-nociceptive properties of Blepharis maderaspatensis leaves. Brazilian J Pharmacogn 2013;23:830-5.
[26]. Yong YK, Sulaiman N, Hakim MN, Lian GE, Zakaria ZA, Othman F, et al. Suppressions of serotonin-induced increased vascular permeability and leukocyte infiltration by Bixa Orellana leaf extract. Biomed Res Int 2013;463145
[27]. Patil KR, Mahajan UB, Unger BS, Goyal SN, Belemkar S, Surana SJ, et al. Animal models of inflammation for screening of anti-inflammatory drugs: Implications for the discovery and development of phytopharmaceuticals. Int J Mol Sci 2019;20:1-38.